

Non-surgical Treatment of Anterior Open Bite and Its Assessment Using the Dawjee Analysis: A Case Report

SADJ May 2008, Vol 63 no 4 p 234 - 238

S.M. Dawjee: B.Ch.D, Hons, M.Sc. (Odont), M.Dent. (Orthodontics). Senior Specialist, Department of Orthodontics, University of Pretoria.

T.G. Oberholzer: B.Sc, B.Ch.D, P.D.D., M.Sc, Ph.D. Department of Operative Dentistry, Medunsa Oral Health Centre, University of Limpopo.

P. Hlongwa: BOH, BDS, M.Dent. (Orthodontics). Head of the Department of Orthodontics, Medunsa Oral Health Centre, University of Limpopo.

Corresponding Author:

S.M. Dawjee: Department of Orthodontics, University of Pretoria, P.O. Box 1266, Pretoria, 0001. E-mail: s.dawjee@up.ac.za

ABSTRACT

Anterior open bite (AOB) is a dentofacial problem occurring more commonly in race groups of African origin¹. Although multi-factorial, the aetiology exerts its influence in tandem with craniofacial development. Diagnosis is confirmed by a cephalometric assessment and points either to a skeletal origin, a dental source, or both. Depending on the time of diagnosis and severity of the condition, treatment can vary from interceptive procedures, orthodontics only, or a combination of orthodontic treatment and orthognathic surgery.

A case study is presented of an adult female with AOB who was treated non-surgically. The diagnosis, treatment technique and outcome are described, as well as a pre- and post-treatment evaluation of the cephalograms using the Dawjee analysis. Comparison of pre- and post-treatment cephalometric values show a definite dentofacial improvement, and identifies specific morphologic areas that have changed as a result of treatment. Transformations in anteroposterior maxillary and mandibular positions and orientation are readily detectable, as well as a repositioning of the alveolar processes.

While pre and post treatment cephalometric values presented for this patient compare well, these values are case specific and cannot be implemented

widely unless the analysis is applied to a larger and more representative population sample and standardised measurements have been established.

Keywords: Anterior open bite, Cephalometric analysis, Orthodontic treatment

INTRODUCTION

Anterior open bite (AOB) malocclusion is a common orthodontic concern and according to Beane¹ the NHANES III study cites that the condition can occur from 2,5 to 4 times more often in Blacks than in Whites. Aetiological factors that have been implicated in the development of the condition include unfavourable growth pattern², finger sucking habits³, enlarged lymphoid tissue⁴, abnormal tongue and orofacial muscular activity⁵, and genetics⁶. These factors can result in a dental open bite, a skeletal open bite, or a combination of the two⁷.

It is essential that the clinician recognises the various aetiological components causing the AOB and their effect on craniofacial morphology so that the appropriate treatment may be undertaken. While most AOBs in the primary and mixed dentition correct spontaneously⁸, various treatment options are available to manage those AOBs that persist. These treatment modalities are dictated by the underlying aetiology and include orthodontics only, orthognathic surgery, or a combination of the two^{9,10}.

CASE PRESENTATION

A 23-year old Black female patient presented at the Orthodontic Department of the Medunsa Oral Health Centre (MOHC), University of Limpopo, South Africa, complaining that her upper and lower front teeth did not meet. She had no family history of the condition and a dental history revealed that she had a habit of thumb sucking until the age of 12.

Clinically the following was noted (figs. 1 - 5):

1. A bimaxillary protrusive facial profile
2. Incompetent lips at rest
3. Disclusion of the upper and lower anterior teeth from 3 to 3
4. An anterior open bite of 7mm
5. Incisal wear of the 11 and 21
6. Class I buccal occlusion on left side and a half cusp Class II on the right side
7. Two millimetres of spacing mesially and distally on both the 13 and 23
8. Six millimetres of spacing between the lower incisors from 33 to 43

Oral hygiene, speech and swallowing were normal and the patient had no other dentofacial concerns. Because the habit had stopped eleven years ago and the patient's growth was complete, orthodontics, or a combination of orthodontics and orthognathic surgery, were the only treatment options available. The patient was, however, reluctant to undergo any form of surgery.

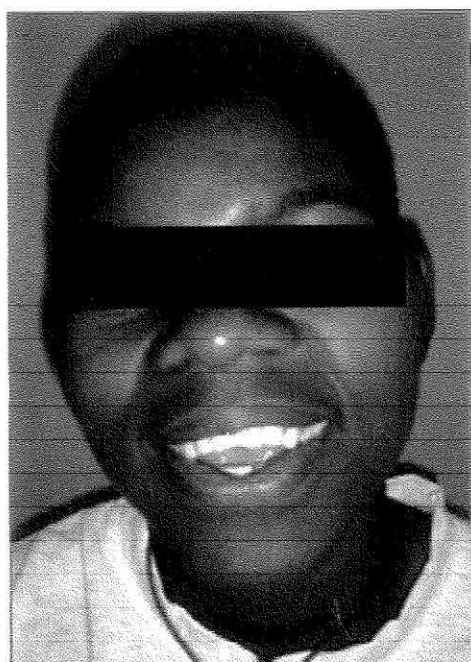


Fig. 1. Pretreatment frontal view of the face

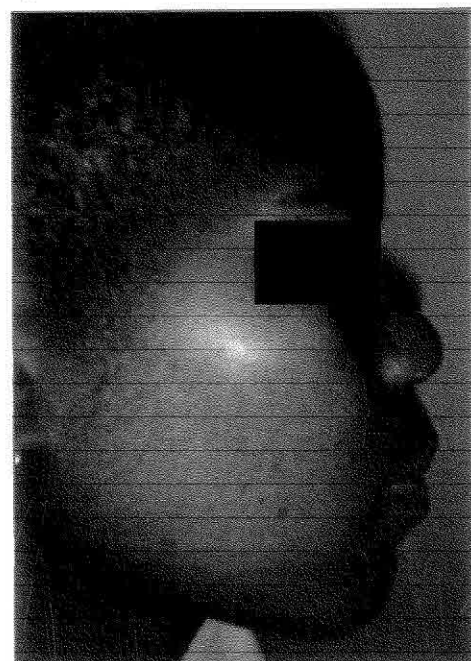


Fig. 2. Pretreatment lateral view of the face

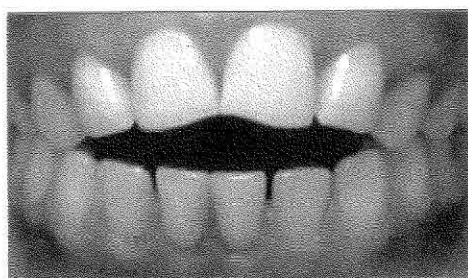


Fig. 3. Pretreatment anterior occlusal view

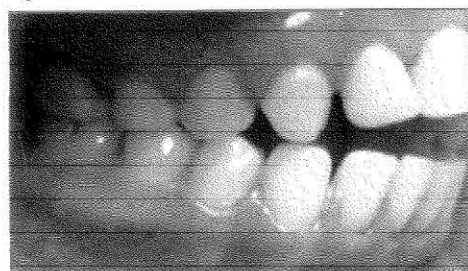


Fig. 4. Pretreatment right occlusal view




Fig. 5. Pretreatment left occlusal view

per and lower 2x4 utility archwires with reverse tip back bends mesial to the first molars. This was followed with full archwires swept with reverse curves of Spee. Final archwires were supplemented with anterior elastics to maintain bite closure.

At the end of treatment acceptable results were achieved with a normal overbite and overjet of 2mm each. Buccal occlusion on the left was Class I while the right side remained half cusp Class II, accounting for an upper midline shift of 3mm to the left (Figs. 6-10). Retention was maintained for a year and consisted of fixed upper and lower 3-3 retainers.

CEPHALOMETRIC ANALYSIS

While various cephalometric analyses are available to diagnose and identify the morphological components of an AOB¹¹⁻¹⁴, these methods are not race specific and standardised values for the South African Black race group are not available. To this end a new system of evaluating AOB, the Dawjee Analysis¹⁵, has been designed for this ethnic group. This analysis is primarily focused

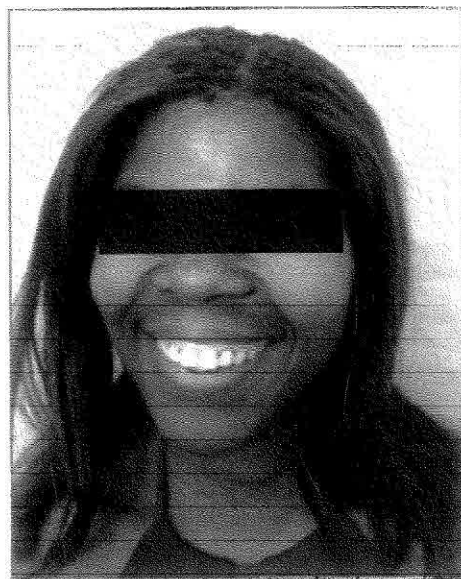


Fig. 6. Post-treatment frontal view of the face



Fig. 7. Post-treatment lateral view of the face

on evaluating craniofacial structures in the vertical dimension.

DISCUSSION

Although the orthodontic treatment of this patient was without incident, some biomechanical observations need reflection. While the first premolars were considered for extraction and by way of the drawbridge concept¹⁶, would have resulted in bite closure, a reduction of the bimaxillary protrusion, midline correction and a defined Class I occlusion; the patient was happy with

From an orthodontic perspective, two treatment modalities were proposed to manage the AOB:

1. Extraction of upper and lower premolars followed by full fixed orthodontics, or
2. Non-extraction full fixed orthodontic therapy only.

After informed deliberation, the patient opted for the second treatment plan.

Active treatment lasted for approximately 15 months and consisted initially of up-

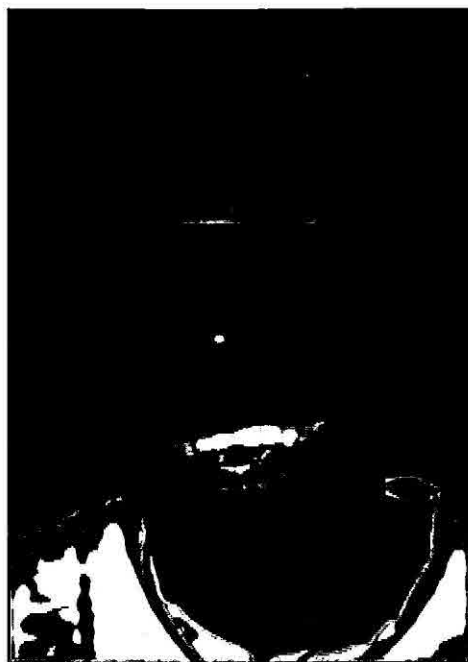

Fig. 1. Pretreatment frontal view of the face




Fig. 2. Pretreatment lateral view of the face

From an orthodontic perspective, two treatment modalities were proposed to manage the AOB:

1. Extraction of upper and lower premolars followed by full fixed orthodontics, or
2. Non-extraction full fixed orthodontic therapy only.

After informed deliberation, the patient opted for the second treatment plan.

Active treatment lasted for approximately 15 months and consisted initially of up-

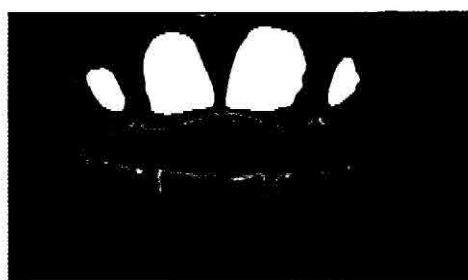


Fig. 3. Pretreatment anterior occlusal view



Fig. 4. Pretreatment right occlusal view



Fig. 5. Pretreatment left occlusal view

per and lower 2x4 utility archwires with reverse tip back bends mesial to the first molars. This was followed with full archwires swept with reverse curves of Spee. Final archwires were supplemented with anterior elastics to maintain bite closure.

At the end of treatment acceptable results were achieved with a normal overbite and overjet of 2mm each. Buccal occlusion on the left was Class I while the right side remained half cusp Class II, accounting for an upper midline shift of 3mm to the left (Figs. 6-10). Retention was maintained for a year and consisted of fixed upper and lower 3-3 retainers.

CEPHALOMETRIC ANALYSIS

While various cephalometric analyses are available to diagnose and identify the morphological components of an AOB¹¹⁻¹⁴, these methods are not race specific and standardised values for the South African Black race group are not available. To this end a new system of evaluating AOB, the Dawjee Analysis¹⁵, has been designed for this ethnic group. This analysis is primarily focused




Fig. 6. Post-treatment frontal view of the face



Fig. 7. Post-treatment lateral view of the face

on evaluating craniofacial structures in the vertical dimension.

DISCUSSION

Although the orthodontic treatment of this patient was without incident, some biomechanical observations need reflection. While the first premolars were considered for extraction and by way of the drawbridge concept¹⁶, would have resulted in bite closure, a reduction of the bimaxillary protrusion, midline correction and a defined Class I occlusion; the patient was happy with




Fig. 8. Post-treatment anterior occlusal view

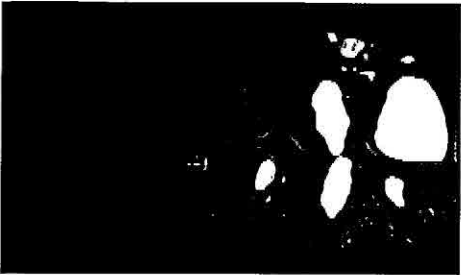

Fig. 9. Post-treatment right occlusal view




Fig. 10. Post-treatment left occlusal view

Table 1. Comparison of pre- and post-treatment cephalometric values

	Pre-treatment values	Post-treatment values
Anterior cranial base inclination	5°	5°
Anterior cranial base length	68 mm	68 mm
Anterior maxillary position	30°	33°
Posterior maxillary position	43°	41°
Anterior mandibular position	64°	65°
Posterior mandibular position	34°	39°
Point A position	34°	37°
Point B position	56°	58°
Inter-alveolar angle	83°	75°
Apex of the maxillary triangle	107°	106°
Apex of the mandibular triangle	82°	76°

her horizontal facial profile and did not want to have any teeth removed. Furthermore, extractions could encroach on tongue space and may have compromised post-treatment stability.

Reverse tipback bends in a utility archwire are effective in extruding incisors, but cause reciprocal mesialization and buccal displacement of molars. This problem can be overcome with the use of transpalatal and lingual arches. To retain overbite correction it is essential

that anterior box elastics are used when full archwires are inserted and posterior segments leveled. Post-treatment intraoral photographs (figs. 8-10) were taken immediately after a scaling and accounts for the irritation and bleeding around the gingival margins. Photographs could not be taken later when the gingival healed, as the patient relocated immediately after deband.

Lingually bonded fixed retainers were preferred instead of removable

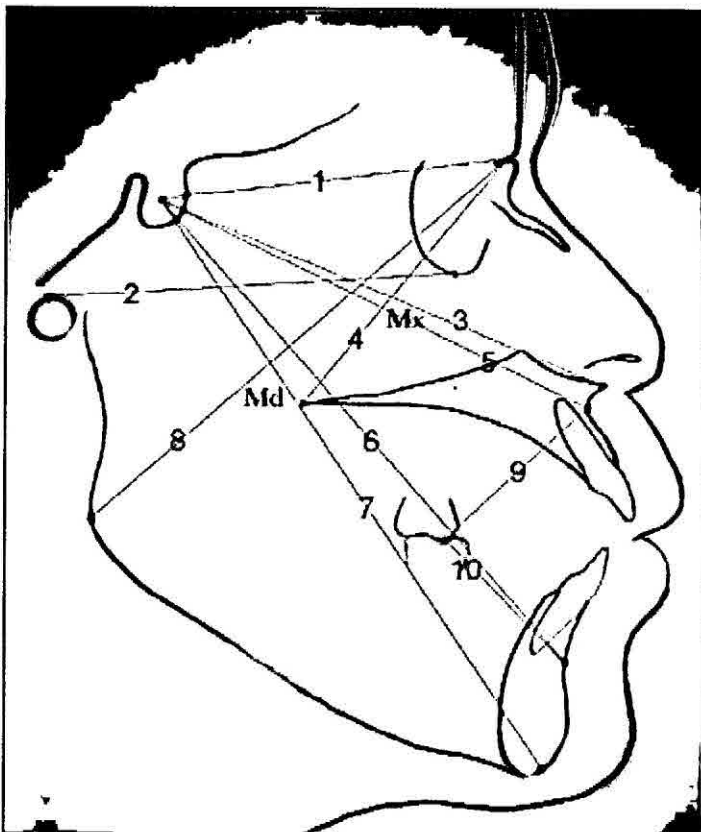


Fig. 11. Pre-treatment lateral cephalogram demonstrating lines and planes used in the Dawjee analysis¹⁵




Fig. 12. Analysis of the post-treatment lateral cephalogram.

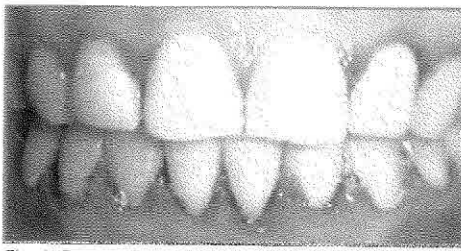


Fig. 8. Post-treatment anterior occlusal view

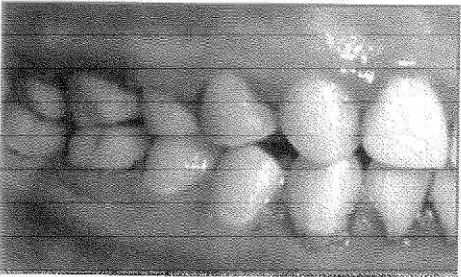

Fig. 9. Post-treatment right occlusal view

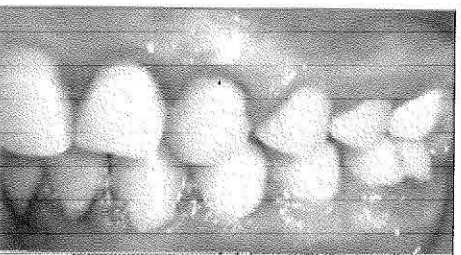

Fig. 10. Post-treatment left occlusal view

Table 1. Comparison of pre- and post-treatment cephalometric values

	Pre-treatment values	Post-treatment values
Anterior cranial base inclination	5°	5°
Anterior cranial base length	68 mm	68 mm
Anterior maxillary position	30°	33°
Posterior maxillary position	43°	41°
Anterior mandibular position	64°	65°
Posterior mandibular position	34°	39°
Point A position	34°	37°
Point B position	56°	58°
Inter-alveolar angle	83°	75°
Apex of the maxillary triangle	107°	106°
Apex of the mandibular triangle	82°	76°

her horizontal facial profile and did not want to have any teeth removed. Furthermore, extractions could encroach on tongue space and may have compromised post-treatment stability.

Reverse tipback bends in a utility archwire are effective in extruding incisors, but cause reciprocal mesialization and buccal displacement of molars. This problem can be overcome with the use of transpalatal and lingual arches. To retain overbite correction it is essential

that anterior box elastics are used when full archwires are inserted and posterior segments leveled. Post-treatment intraoral photographs (figs. 8-10) were taken immediately after a scaling and accounts for the irritation and bleeding around the gingival margins. Photographs could not be taken later when the gingival healed, as the patient relocated immediately after deband.

Lingually bonded fixed retainers were preferred instead of removable

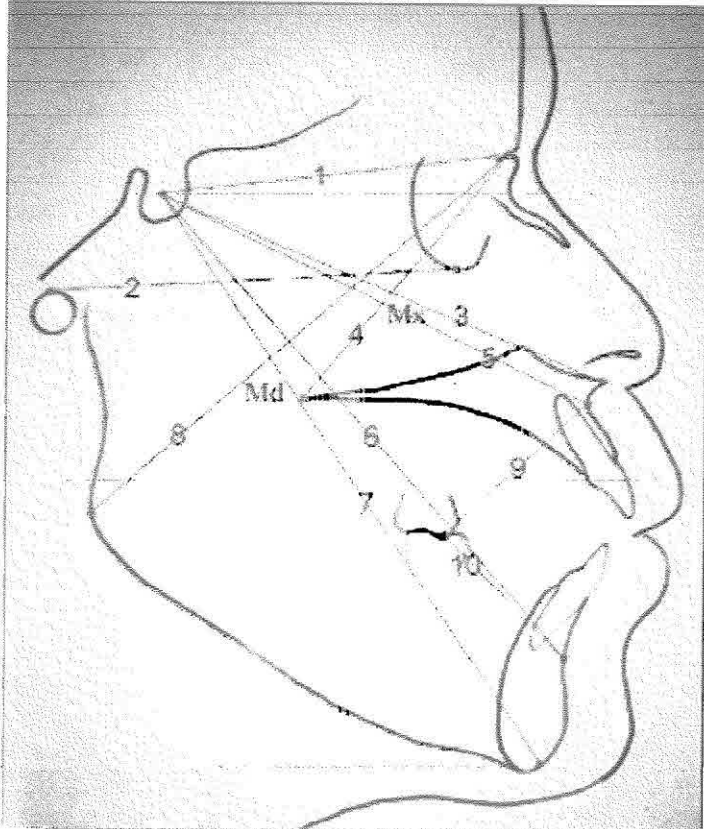


Fig. 11. Pre-treatment lateral cephalogram demonstrating lines and planes used in the Dawjee analysis¹⁹

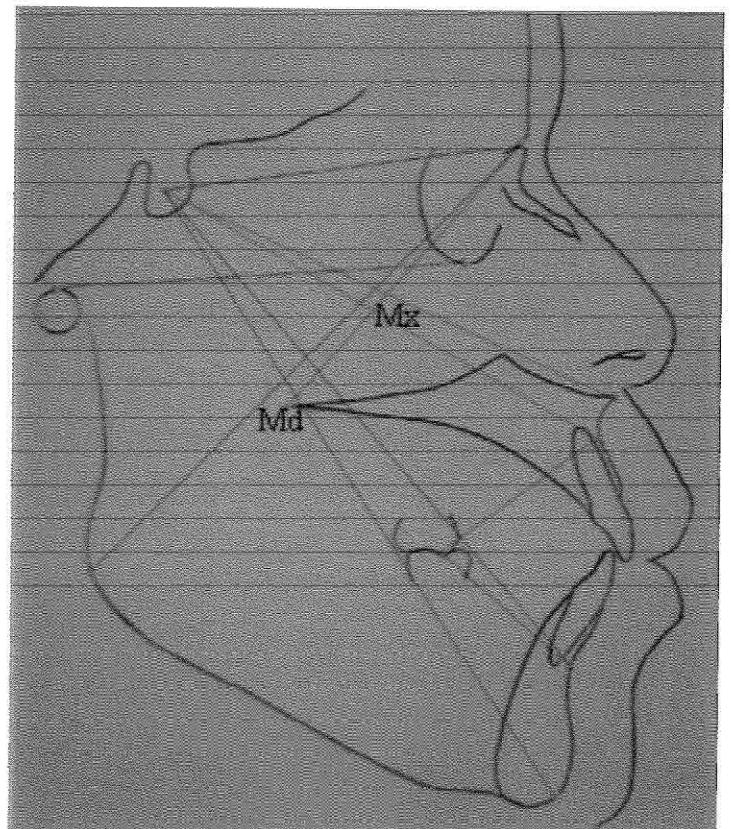


Fig. 12. Analysis of the post-treatment lateral cephalogram.

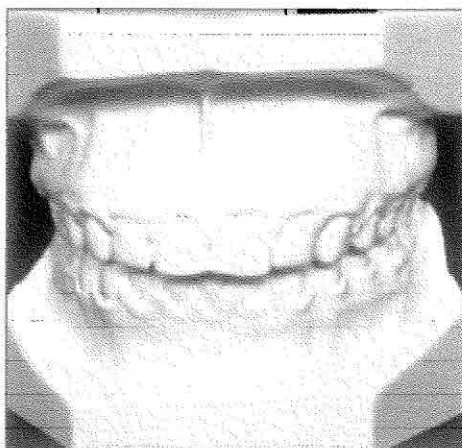


Fig. 13. Post retention cast – frontal view

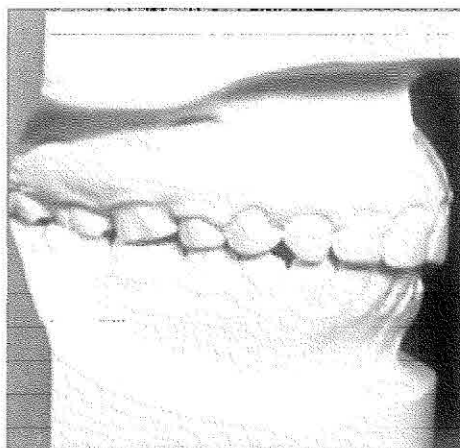


Fig. 14. Post retention cast – right view

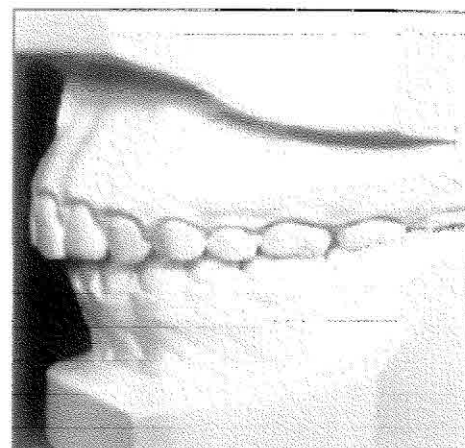


Fig. 15. Post retention cast – left view

retainers as the former are less likely to interfere with the posterior occlusion and risk the possibility of relapse. As the patient relocated to a rural district after treatment, study casts that were sent to the Orthodontic Department approximately a year after treatment, show no evidence of relapse (Figs. 13-15). Service limitation in the patient's location ruled out an orthopantomogram or lateral cephalogram.

When the values between pre-treatment (fig.11) and post-treatment (fig.12) tracings are compared (table I), it is evident and obvious that the cranial base length and inclination did not change. Treatment changes in the palatal plane point to a clockwise rotation and while the anterior mandibular position (Gn) remained unchanged, the mandibular angle rotated counter clockwise.

Anterior inter-alveolar distance decreased remarkably with treatment as evidenced by a downward repositioning of point A by three degrees, a decrease in inter-alveolar angle of eight degrees and the establishment of a positive overbite of two millimetres.

A reduction in the mandibular angle (Md) of the mandibular triangle should be interpreted with caution. While this angle is dominated by mandibular length, which in this case has not changed, the four degrees loss in Md must be due to a downward and forward repositioning of Go as confirmed by the five degree gain in posterior mandibular position.

CONCLUSION

Malocclusion in the vertical dimension is a common phenomenon¹⁷, manifesting clinically as either an open or a deep bite. Identification of the morphological traits and source of the problem so as to apply the appropriate treatment can often be confusing and cumbersome¹⁸. By determining mandibular and maxillary positions and alveolar location in the vertical plane, the Dawjee analysis¹⁵ hopes to clear some of the uncertainties surrounding the diagnoses and management of vertical craniofacial abnormalities.

While this patient was treated to a favourable and stable functional and aesthetic result, and post-treatment cephalometric readings show marked improvement, these readings are case specific and cannot be implemented widely unless the analysis is applied to a larger and more representative sample.

Research is currently in progress as part of a thesis to develop standardised values for the Dawjee analysis, which can have widespread clinical use and assist in comparative craniofacial studies.

The authors wish to express their sincere gratitude to Professor William Wiltshire from the University of Manitoba for his guidance and input.

Declaration: No conflict of interest was declared

REFERENCES

1. Beane RA, Reimann G, Phillips C & Tulloch C. A cephalometric comparison of black open-bite subjects and black normals. *Angle Orthod* 2003; **73**: 294-300.
2. Schudy FF. The rotation of the mandible resulting from growth: its implication in orthodontic treatment. *Angle Orthod* 1965; **35**: 36-50.
3. Mizrahi E. A review of anterior open bite. *Br J Orthod* 1978; **5**: 21-7.
4. Linder-Aronson S. Adenoids – their effect on the mode of breathing and nasal air flow and their relationship to characteristics of the facial skeleton and dentition. *Acta Otolaryngol Suppl* 1970; **265**.
5. Moss ML & Salentijn L. Differences between functional matrices in open-bite and in deep overbite. *Am J Orthod* 1971; **60**: 264-80.
6. Swineheart EW. A clinical study of open bite. *Am J Orthod Surg* 1942; **28**: 18-34.
7. Richardson A. Skeletal factors in anterior open-bite and deep overbite. *Am J Orthod* 1969; **56**: 114-27.
8. Worms WF, Meksins LH & Isaacson RJ. Open bite. *Am J Orthod* 1971; **59**: 589-95.
9. Burford D & Noar JH. The causes, diagnoses and treatment of anterior open bite. *Dental Update* 2003; **30**: 235-41.
10. Epker B & Fish L. Surgical correction of open bite deformity. *Am J Orthod* 1977; **71**: 278-99.
11. Nahoum HL. Anterior open bite: A cephalometric analysis and suggested treatment procedures. *Am J Orthod* 1975; **67**: 513-521.
12. Sassouni V & Nanda S. Analysis of dentofacial vertical proportions. *Am J Orthod* 1964; **50**: 801-23.
13. Tweed CH. Frankfort mandibular plane angle in orthodontic diagnosis, classification, treatment planning and prognosis. *Am J Orthod* 1946; **32**: 175-230.
14. Kim YH. Overbite depth indicator with particular reference to anterior open bite. *Am J Orthod* 1974; **65**: 586-611.

Additional references (15-18) are available on www.sadanet.co.za

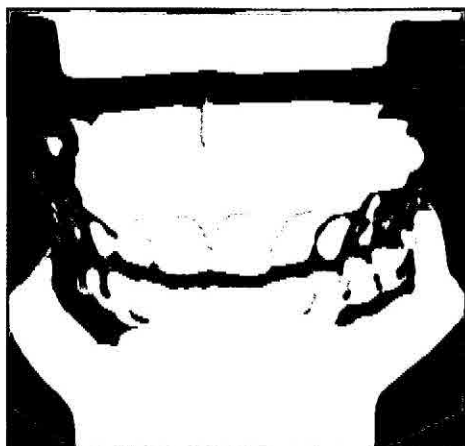


Fig. 13. Post retention cast – frontal view

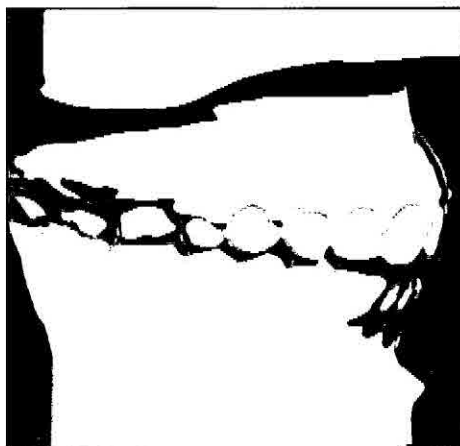


Fig. 14. Post retention cast – right view

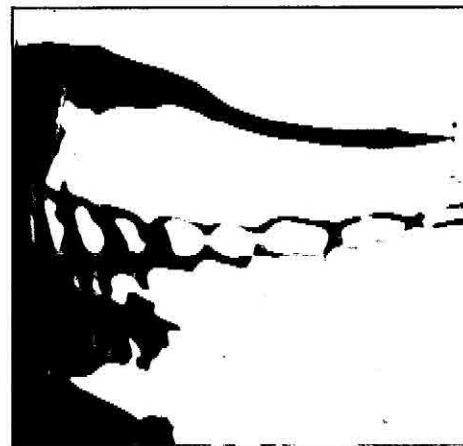


Fig. 15. Post retention cast – left view

retainers as the former are less likely to interfere with the posterior occlusion and risk the possibility of relapse. As the patient relocated to a rural district after treatment, study casts that were sent to the Orthodontic Department approximately a year after treatment, show no evidence of relapse (Figs. 13-15). Service limitation in the patient's location ruled out an orthopantomogram or lateral cephalogram.

When the values between pre-treatment (fig.11) and post-treatment (fig.12) tracings are compared (table I), it is evident and obvious that the cranial base length and inclination did not change. Treatment changes in the palatal plane point to a clockwise rotation and while the anterior mandibular position (Gn) remained unchanged, the mandibular angle rotated counter clockwise.

Anterior inter-alveolar distance decreased remarkably with treatment as evidenced by a downward repositioning of point A by three degrees, a decrease in inter-alveolar angle of eight degrees and the establishment of a positive overbite of two millimetres.

A reduction in the mandibular angle (Md) of the mandibular triangle should be interpreted with caution. While this angle is dominated by mandibular length, which in this case has not changed, the four degrees loss in Md must be due to a downward and forward repositioning of Go as confirmed by the five degree gain in posterior mandibular position.

CONCLUSION

Malocclusion in the vertical dimension is a common phenomenon¹⁷, manifesting clinically as either an open or a deep bite. Identification of the morphological traits and source of the problem so as to apply the appropriate treatment can often be confusing and cumbersome¹⁸. By determining mandibular and maxillary positions and alveolar location in the vertical plane, the Dawjee analysis¹⁵ hopes to clear some of the uncertainties surrounding the diagnoses and management of vertical craniofacial abnormalities.

While this patient was treated to a favourable and stable functional and aesthetic result, and post-treatment cephalometric readings show marked improvement, these readings are case specific and cannot be implemented widely unless the analysis is applied to a larger and more representative sample.

Research is currently in progress as part of a thesis to develop standardised values for the Dawjee analysis, which can have widespread clinical use and assist in comparative craniofacial studies.

The authors wish to express their sincere gratitude to Professor William Wiltshire from the University of Manitoba for his guidance and input.

Declaration: No conflict of interest was declared

REFERENCES

1. Beane RA, Reimann G, Phillips C & Tulloch C. A cephalometric comparison of black open-bite subjects and black normals. *Angle Orthod* 2003; **73**: 294-300.
2. Schudy FF. The rotation of the mandible resulting from growth: its implication in orthodontic treatment. *Angle Orthod* 1965; **35**: 36-50.
3. Mizrahi E. A review of anterior open bite. *Br J Orthod* 1978; **5**: 21-7.
4. Linder-Aronson S. Adenoids – their effect on the mode of breathing and nasal air flow and their relationship to characteristics of the facial skeleton and dentition. *Acta Otolaryngol Suppl* 1970; **265**.
5. Moss ML & Salentijn L. Differences between functional matrices in open-bite and in deep overbite. *Am J Orthod* 1971; **60**: 264-80.
6. Swineheart EW. A clinical study of open bite. *Am J Orthod Surg* 1942; **28**: 18-34.
7. Richardson A. Skeletal factors in anterior open-bite and deep overbite. *Am J Orthod* 1969; **56**: 114-27.
8. Worms WF, Meksins LH & Isaacson RJ. Open bite. *Am J Orthod* 1971; **59**: 589-95.
9. Burford D & Noar JH. The causes, diagnoses and treatment of anterior open bite. *Dental Update* 2003; **30**: 235-41.
10. Epker B & Fish L. Surgical correction of open bite deformity. *Am J Orthod* 1977; **71**: 278-99.
11. Nahoum HI. Anterior open bite: A cephalometric analysis and suggested treatment procedures. *Am J Orthod* 1975; **67**: 513-521.
12. Sassouni V & Nanda S. Analysis of dentofacial vertical proportions. *Am J Orthod* 1964; **50**: 801-23.
13. Tweed CH. Frankfort mandibular plane angle in orthodontic diagnosis, classification, treatment planning and prognosis. *Am J Orthod* 1946; **32**: 175-230.
14. Kim YH. Overbite depth indicator with particular reference to anterior open bite. *Am J Orthod* 1974; **65**: 586-611.

Additional references (15-18) are available on www.sadanet.co.za