




87054677

Research



Back, chest and abdominal pain

How good are spinal signs at identifying musculoskeletal causes of back, chest or abdominal pain?

Michael J Yelland

Michael J Yelland, MBBS, FRACGP, FAFMM, GdipMuscMed, is Senior Lecturer in General Practice, University of Queensland.

BACKGROUND Spinal signs found in association with atypical chest and abdominal pain may suggest the pain is referred from the thoracic spine. However, the prevalence of such signs in these conditions has rarely been compared with that in those without pain. In this study, the prevalence of spinal signs and dysfunction in patients with back, chest and abdominal pain is compared with that in pain free controls. The aim of the study is to determine the significance of spinal findings in patients with such pain.

METHODS A general practitioner blinded to the patients' histories performed a cervical and thoracic spinal examination on general practice patients with back, chest and/or abdominal pain and on controls without pain. Thoracic intervertebral dysfunction was diagnosed on the basis of movement and palpation findings.

RESULTS Seventy-three study patients plus 24 controls, were examined. For cervical spinal signs, pain in the back, chest and/or abdomen was associated with pain with active movements and overpressure at end range and with loss of movement range. For thoracic spinal signs, this association held for pain with active movements and overpressure, but not with loss of movement range.

The prevalence of thoracic intervertebral dysfunction was 25.0% in controls, 65.5% with chest/abdominal pain, 72.0% with back pain and 79.0% with back pain with chest/abdominal pain. This prevalence was higher with chest pain than with abdominal pain.

CONCLUSIONS The results show an association, but not a causal link between thoracic intervertebral dysfunction and atypical chest/abdominal pain. A spinal examination should be performed routinely assessing these conditions. The minimum examination for the detection of intervertebral dysfunction is testing for pain with spinal movements and palpation for tenderness. The interpretation of positive signs requires knowledge of their prevalence in pain free controls and in patients with visceral disease.

Received 19 March 2001; accepted 22 May 2001

The patient with 'atypical' chest or abdominal pain, for which no cause is found despite detailed clinical assessment and investigation for cardiovascular, respiratory and intra-abdominal causes is a difficult scenario in general practice and emergency units. Without a positive diagnosis of the cause, treatment becomes nonspecific and symptomatic only.

There are reports in the literature¹⁻⁵ where 'atypical' chest or abdominal pain has been attributed to disorders of the

thoracic spine. The diagnosis typically relies on recognition of thoracic spinal pain referral patterns,^{6,7} pain and stiffness on spinal movements and palpation, and a response to spinal treatments. Such diagnoses are self supporting and subject to bias from the diagnostic orientation of the examining clinician. They are made without evidence that the prevalence of spinal signs in patients with pain is any greater than in pain free controls.

Intervertebral dysfunction in this study is defined as 'reversible, benign, painful, segmental vertebral dysfunction of mechanical and reflex origin'.⁸ It is attributed to a spinal motion segment or segments and focuses on a disturbance of function without implicating a specific structure such as a degenerate facet joint or disc.

Study aim

This study compares the prevalence of spinal signs and thoracic intervertebral



dysfunction in groups of subjects with chest, back and/or abdominal pain referred from GPs, with a control group without pain. It thereby aims to determine the significance of spinal findings in patients with these symptoms. The back examination method widely taught to Australian GPs is used.²

Methods

Recruitment

The study was conducted from November 1996 to December 1997 in the Inala Community Health Centre in Brisbane. An assessment clinic was established for patients with back, chest and/or abdominal pain without a clearly defined pathology. Subjects were referred by local GPs and were eligible for the study if they had fulfilled one or more of the following criteria in the preceding month:

- back pain located between the cervico-thoracic junction and the iliac crests, the latter being recognised as a site of referred pain from the lowest thoracic spinal segment¹⁰
- chest pain for which an ECG was performed
- abdominal pain for which an upper endoscopy had been ordered and/or performed.

The latter two criteria were chosen to include patients in whom a visceral pathology had been considered in the differential diagnosis.

Control subjects were chosen and contacted using a stratified random sample from the patient register in the group practice of the examining doctor. They were excluded if they had been seen by the examining doctor for back, chest or abdominal pain in the preceding six months. The age range of both pain and control subjects was limited to 20–75 years.

Ethics approval was obtained from the University of Queensland clinical research ethics committee and informed consent was obtained from all subjects.

Examination procedure

The examining doctor was a GP with a postgraduate qualification and nine years experience in musculoskeletal medicine. He was blinded to the histories of the study patients to reduce diagnostic bias. The Kenna/Murtagh method of back examination was used. This included:

- inspection of the standing thoracic spinal posture for abnormal kyphosis and scoliosis
- flexion, extension, sidebending and rotation movements in the cervical and thoracic spines. All movements were tested in the sitting position for:
 - loss of range determined by clinical knowledge of normal values for age and, for sidebending and rotation, comparing ranges for each side
 - pain with active movements
 - pain with overpressure at the end of range
 - cervical spinal movements were included, as the cervical spine has been shown to be a source of thoracic spinal pain^{10,11}
- palpation for tenderness of thoracic spinous processes, facet joints, costovertebral joints and the associated paraspinal muscles.

Based on this examination, subjects were categorised as having:

- thoracic intervertebral dysfunction
- no intervertebral dysfunction or
- generalised tenderness.

Analysis

Subjects with pain were grouped according to the site of their pain. Chi-squared tests, using SAS Version 6.12, were performed on group data with the associated probability values of 0.05 or less being considered clinically significant for differences among groups. The prevalence of signs and intervertebral dysfunction was expressed as a percent, and then compared between the pain groups and the control group.

Results

Ninety-seven subjects who satisfied the inclusion criteria of the study were examined. Table 1 outlines their demographic details. Their categorisation by symptoms is shown in Figure 1. The control group had 24 subjects.

Table 1. Characteristics of the 97 patients examined in the study

Characteristic	n	%
Sex		
Male	43	44.3
Female	54	55.7
Age		
20–29	5	5.2
30–39	14	14.4
40–49	21	21.6
50–59	22	22.7
60–69	32	33.0
70–75	3	3.1

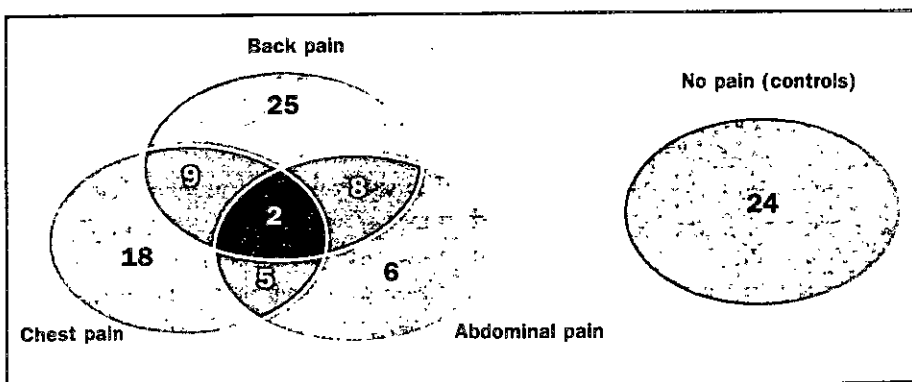


Figure 1. Diagram illustrating the distribution of study patients in each pain group, including those with pain in more than one area and controls with no pain.

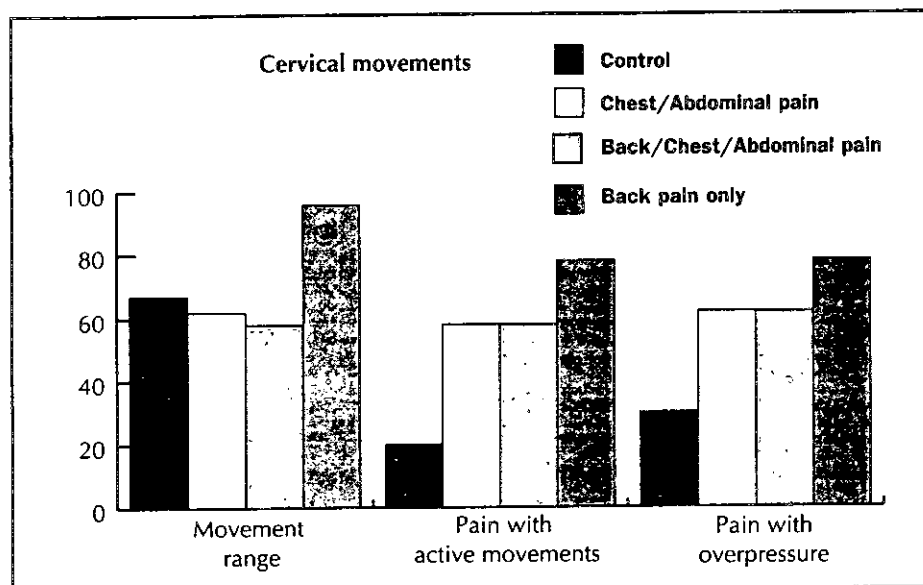


Figure 2. Percentage of control patients and patients with back, chest and/or abdominal pain with positive cervical spinal movement signs. A positive sign is one that affects one or more directions of movement.

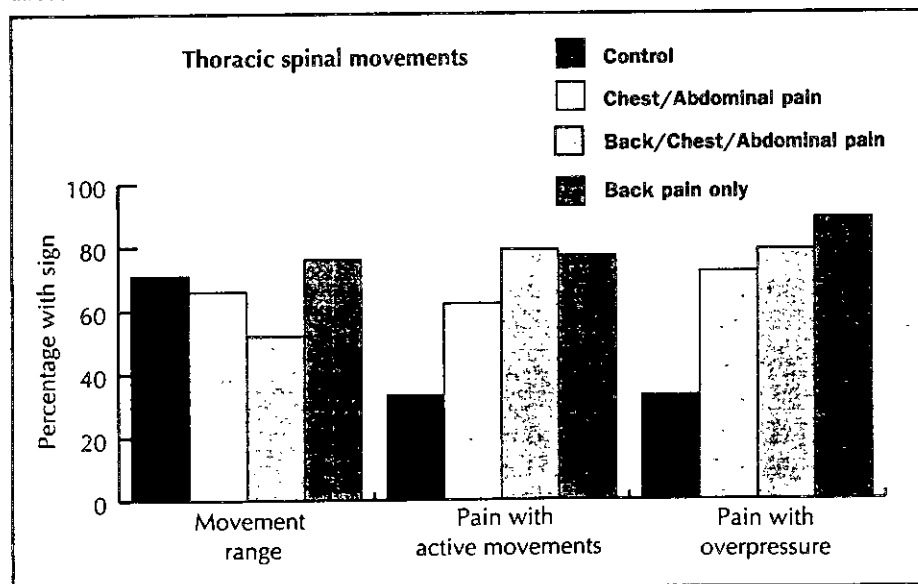


Figure 3. Percentage of control patients and patients with back, chest and/or abdominal pain with positive thoracic spinal movement signs. A positive sign is one that affects one or more directions of movement.

For the purposes of analysis by broad clinical groupings, subjects with pain were categorised into one of the following groups:

- chest and/or abdominal pain (n=29)
- back pain in conjunction with chest and/or abdominal pain (n=19)
- back pain only (n=25).

For cervical spinal examination, loss of range of one or more movements was significantly more common ($p=0.015$) in those with back pain than in the other three groups (Figure 2). In the three pain groups, pain was significantly more common with one or more active movements ($p=0.01$) and with overpressure

($p=0.008$) than in the control group. The prevalence of pain with these movements in the pain groups was 2.1–3.7 times greater than in controls.

For thoracic spinal movements, there were no differences in the prevalence of loss of range among groups. However, pain was significantly more frequent in the three pain groups on one or more active movements ($p=0.013$) and with overpressure ($p=0.0003$) than in the control group (Figure 3), with a prevalence 1.9–2.6 times greater than in controls.

For the total sample:

- intervertebral dysfunction was diagnosed in 58.7%,
- no intervertebral dysfunction in 28.9% and
- generalised tenderness in 11.4%.

Thoracic intervertebral dysfunction was significantly more common in the groups with pain ($p=0.0007$), showing a prevalence 2.6–3.2 times higher than in controls (Figure 4).

With reclassification of the sample by chest or abdominal pain, those with chest pain were more likely to have dysfunction than those with abdominal pain (Figure 5). The prevalence of dysfunction with pain in both the chest and abdomen fell between these two other groups. There was no clear correlation between the level of intervertebral dysfunction and anatomically related region of the chest or abdomen. For example, dysfunction in the lower thoracic spine was not correlated with abdominal pain.

Discussion

Clinical implications

While this study demonstrated a high prevalence of spinal signs and intervertebral dysfunction in those with back, chest and abdominal pain, it also showed a substantial baseline prevalence in pain free controls. Loss of range was present in approximately two-thirds of controls and was not helpful in

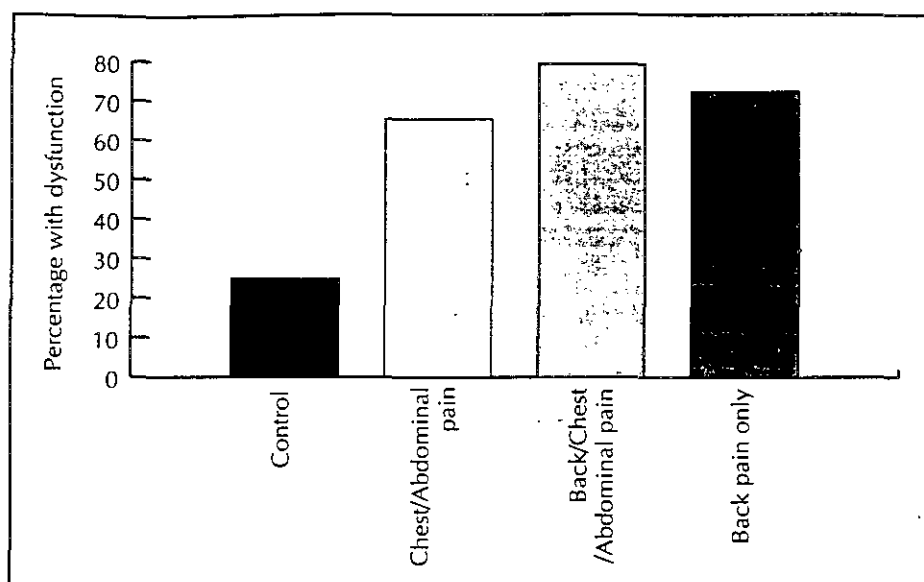


Figure 4. Percentage of control patients and patients with back, chest and/or abdominal pain with a diagnosis of thoracic intervertebral dysfunction. Subjects with any chest or abdominal pain are grouped together.

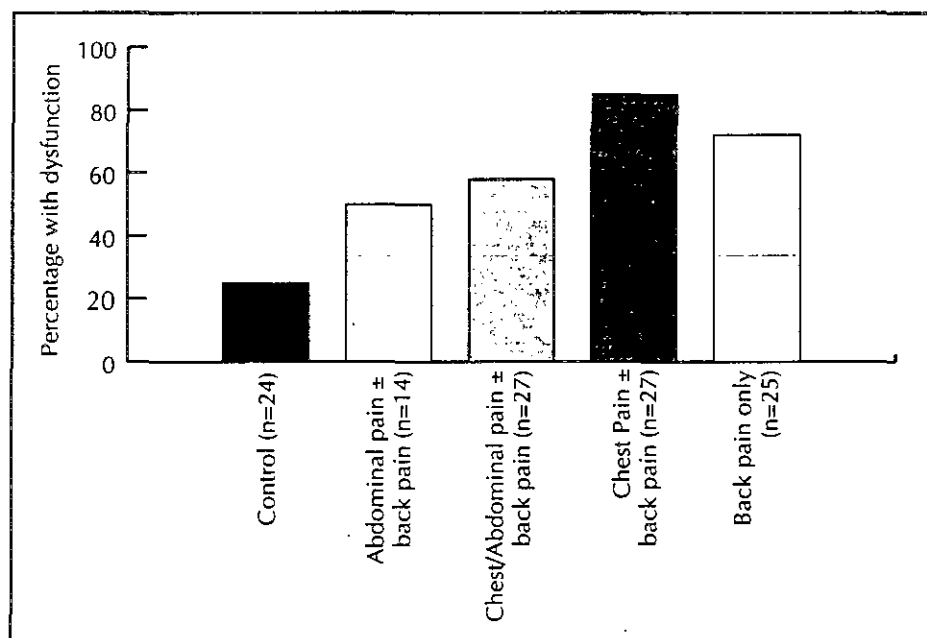


Figure 5. Percentage of control patients and patients with back, chest and/or abdominal pain with a diagnosis of thoracic intervertebral dysfunction. Subjects with any chest pain, abdominal pain or both, are grouped separately.

differentiating them from subjects with pain. Pain with spinal movements, tenderness and intervertebral dysfunction were clearly associated with the pain groups, but were still present in up to a third of control subjects. A prevalence of 37% of pain or discomfort has been reported elsewhere in palpation of T1-8 in asymptomatic controls,

this being most common at T3-5, the stiffest part of the thoracic spine.¹²

These results suggest that in the interpretation of musculoskeletal signs in back, chest and abdominal pain the most clinical significance can be placed on:

- pain on active movements
- pain with overpressure at end range

- palpation for spinal and paraspinal tenderness.

Minor postural abnormalities and loss of movement range show little association with pain.

Although intervertebral dysfunction is a clinically useful diagnosis, proof that it is the source of referred pain is limited by the lack of a readily available confirmatory test.

In diagnosing referred pain, knowledge of patterns of referral can be gained from experimental studies of injections of spinal structures in normal volunteers. Here, injections of irritant solutions into thoracic interspinous ligaments and paraspinal structures have resulted in the referral of pain into the chest and abdominal walls both posteriorly and anteriorly.^{6,7,13} This pain is described as deep, dull and aching; it tends to be poorly localised, but is approximately segmental in nature. Other studies of the response to distension of zygapophyseal joints in normal volunteers and patients have shown referral of pain inferiorly and laterally as far as the posterior axillary line.^{9,14,15}

To complicate matters, musculoskeletal signs may also be a marker of several visceral diseases. One of the subjects in this study, with an examination diagnosis of upper thoracic dysfunction, was subsequently diagnosed with apical lung carcinoma. In patients with acute myocardial infarction and other types of heart disease, changes in the paravertebral tissues of the left upper thoracic spine, suggestive of intervertebral dysfunction, have been shown to be more common than in controls.¹⁶ Other musculoskeletal signs have been documented in patients with chest pain. Spinal and chest wall tenderness and painful cervical spinal movements have been found in patients with chest pain and negative coronary angiography but not in controls without chest pain.¹⁷ Finally, pleuritic posterior chest pain has been reproduced by palpation of the costovertebral joints or ribs from T4-8 and then relieved by intercostal nerve block.¹⁸



Conclusion

While not confirming a causal link between thoracic intervertebral dysfunction and chest and/or abdominal pain, the results suggest that spinal examination is important in the full assessment of these symptoms. The interpretation of musculoskeletal signs in this setting should be made with the knowledge of the considerable prevalence of positive signs in pain free controls.

Acknowledgments

The contributions of Mrs Anna Nichols to recruitment of control subjects, Mr Robert Kerr to data entry and Dr David Purdie for statistical analysis are gratefully acknowledged.

References

1. Grieve G P, ed. Thoracic joint problems and simulated visceral disease. In: Modern manual therapy of the vertebral column. 1st edn. Melbourne: Churchill-Livingstone, 1986:377-395.
2. Kenna C, Murtagh J. Back pain and spinal manipulation: A practical guide. Sydney: Butterworths, 1989.
3. Hamberg J, Lindahl O. Angina pectoris symptoms caused by thoracic spine disorders. Clinical examination and treatment. Acta Med Scand 1981; (Suppl)644:84-86.
4. Ashby E C. Abdominal pain of spinal origin. Ann R Coll Surg Engl 1977; 59:242-246.
5. Marinacci A A, Courville C B. Radicular syndromes simulating intra-abdominal surgical conditions. Am Surg 1962; 28:59-63.
6. Kellgren J H. On the distribution of pain arising from deep somatic structures with charts of segmental pain areas. Clin Sci 1939; 4:35-46.
7. Feinstein B, Langton J N K, Jameson R M, Schiller F. Experiments of pain referred from deep somatic tissues. J Bone Joint Surg Am 1954; 36-A:981-997.
8. Maigne R. Diagnosis and treatment of pain of vertebral origin. 1st edn. Paris: Williams and Wilkins, 1996:99-108.
9. Fukui S, Ohseto K, Shiotani M. Patterns of pain induced by distending the thoracic zygapophyseal joints. Reg Anaesth 1997; 22:332-336.
10. Cloward R B. Cervical discography: a contribution to the aetiology and mechanism of neck shoulder and arm pain. Ann Surg 1959; 150:1052-1064.
11. Aprill C, Dwyer A, Bogduk N. Cervical zygapophyseal joint pain patterns II: a clinical evaluation. Spine 1990; 15:458-461.
12. Minucci A. Palpation of the thoracic spine (T1 to T8). Proceedings of the Fifth Biennial Conference of the MPAA. Melbourne, 1987:367-376.
13. Hockaday J M, Whitty C W M. Patterns of referred pain in the normal subject. Brain 1967; 90:481-495.
14. Dreyfuss P, Tibiletti C, Dreyer S J. Thoracic zygapophyseal joint pain patterns: a study in normal volunteers. Spine 1994; 19(7):807-811.
15. Dreyfuss P, Tibiletti C, Dreyer S J, Sobel J. Thoracic zygapophyseal joint pain: a review and description of an intra-articular block technique. Pain Digest 1994; 4:46-54.
16. Nicholas A S, DeBias D A, Ehrenfeuchter W, et al. A somatic component to myocardial infarction. Br Med J 1985; 291:13-17.
17. Wise C M, Semble E L, Dalton C B. Musculoskeletal chest wall syndromes in patients with noncardiac chest pain: a study of 100 patients. Arch Phys Med Rehabil 1992; 73:147-149.
18. Arroyo F J, Jolliet P, Junod A F. Costovertebral joint dysfunction: another misdiagnosed cause of atypical chest pain. Postgrad Med J 1992; 68:655-659.

Implications of this study for the GP

- Spinal signs and intervertebral dysfunction are more prevalent in patients with atypical chest and abdominal pain than in pain free controls and may point to the source of the pain. Hence, a spinal examination should be performed in these patients.
- The minimum spinal examination is testing for pain with spinal movements and for tenderness with palpation.
- The interpretation of musculoskeletal signs in this setting should be made with knowledge of the considerable prevalence of positive signs in pain free controls and in patients with visceral disease.

Correspondence

Michael Yelland

Inala Health Centre General Practice
64 Wirraway Pde
Inala, Qld 4077

Email: M.Yelland@spmed.uq.edu.au

Advertisers' Index BY COMPANY

ASTRAZENECA PTY LTD

Atacand 902
Seroquel Inside front cover, 825

ELI LILLY AUSTRALIA

Zyprexa 898, Packshot 907

FERRING PHARMACEUTICALS

Minirin 851

GLAXOSMITHKLINE AUSTRALIA

Flixotide 829
Serevent 840
Havrix 881
Twinrix 879
Typherix 883
Varilrix 888
Zyban 874

IPS MEDICAL SEARCH

Positions vacant 873

MERCK SHARP & DOHME

Fosamax 892

NOVO NORDISK PTY LTD

Kliovance 830

RACGP

GP of the Year Inside back cover

SANOFI SYTHELABO

Stilnox 862

SERVIER LABORATORIES

Coversyl 858
Coversyl Plus 866
Diamicron 852

SIGMA PHARMACEUTICALS

Cilicaine Syringe Packshot 907

TECSANA

EPI-NO Packshot 907

WYETH PHARMACEUTICALS

Efexor 870, 871

BY PRODUCT

Atacand 902
Cilicaine Syringe Packshot 907
Coversyl 858
Coversyl Plus 866
Diamicron 852
Efexor 870, 871
EPI-NO Packshot 907
Flixotide 829
Fosamax 892
GP of the Year Inside back cover
Havrix 881
Kliovance 830
Minirin 851
Positions vacant 873
Serevent 840
Seroquel Inside front cover, 825
Stilnox 862
Twinrix 879
Typherix 883
Varilrix 888
Zyban 874
Zyprexa 898, Packshot 907